

From the Department of Pathology, College of Veterinary Medicine,
Helsinki, Finland.

STUDIES ON THE PATHOLOGY OF DICROCOELIASIS AND FASCIOLIASIS IN THE GOAT

I. THE HISTOPATHOLOGY OF THE LIVER AND BILE DUCTS*

By
Timo Rahko

RAHKO, TIMO: *Studies on the pathology of dicrocoeliasis and fascioliasis in the goat. I. The histopathology of the liver and bile ducts.* Acta vet. scand. 1972, 13, 554—562. — Comparative studies were made on the histopathology of the liver and bile ducts in dicrocoeliasis and fascioliasis of the goat. Investigations revealed certain similarities in the nature of the pathological phenomena produced by *D. dendriticum* and *F. hepatica*. However, a feature peculiar to fascioliasis was the migratory tracks of immature flukes in the liver parenchyma. Further, the lesions produced by fascioliasis were distinctly more pronounced than those present in dicrocoeliasis.

In both parasitic diseases the bile-duct walls showed glandular hyperplasia, increased frequency of goblet cells and globule leucocytes, and extensive fibrosis in the outer layers. The desquamation produced by *Dicrocoelium* remained superficial whereas *Fasciola* was capable of causing deep erosions in the walls of the main bile ducts. The bile-duct walls did not become calcified. Increased fibrosis was present in the interlobular areas, too, but only fascioliasis produced extensive disorganisation of the hepatic architecture, due to the scars originating from repaired migratory tracks. The liver parenchymal cells were degenerated, showed decreased glycogen but were increasingly infiltrated by neutral fats.

Dicrocoelium dendriticum; *Fasciola hepatica*;
liver; bile ducts.

* Supported by a grant from the Finnish Veterinary Medical Foundation.

Dicrocoelium dendriticum and *Fasciola hepatica* have a world-wide geographical distribution and parasitize the bile ducts of many species of animals and man (*Soulsby* 1965, *Sinclair* 1967, *Bengtsson et al.* 1968). Extensive research has been carried out to elucidate the pathological phenomena produced by fascioliasis (reviewed by *Rahko* 1971). On the other hand, the reports dealing with dicrocoeliasis are few in number, and the information on the pathology of the disease is scanty (*Sinclair*). The purpose of this comparative study is to describe the histopathological alterations produced by dicrocoeliasis and fascioliasis in the liver of spontaneously infected goats.

MATERIAL AND METHODS

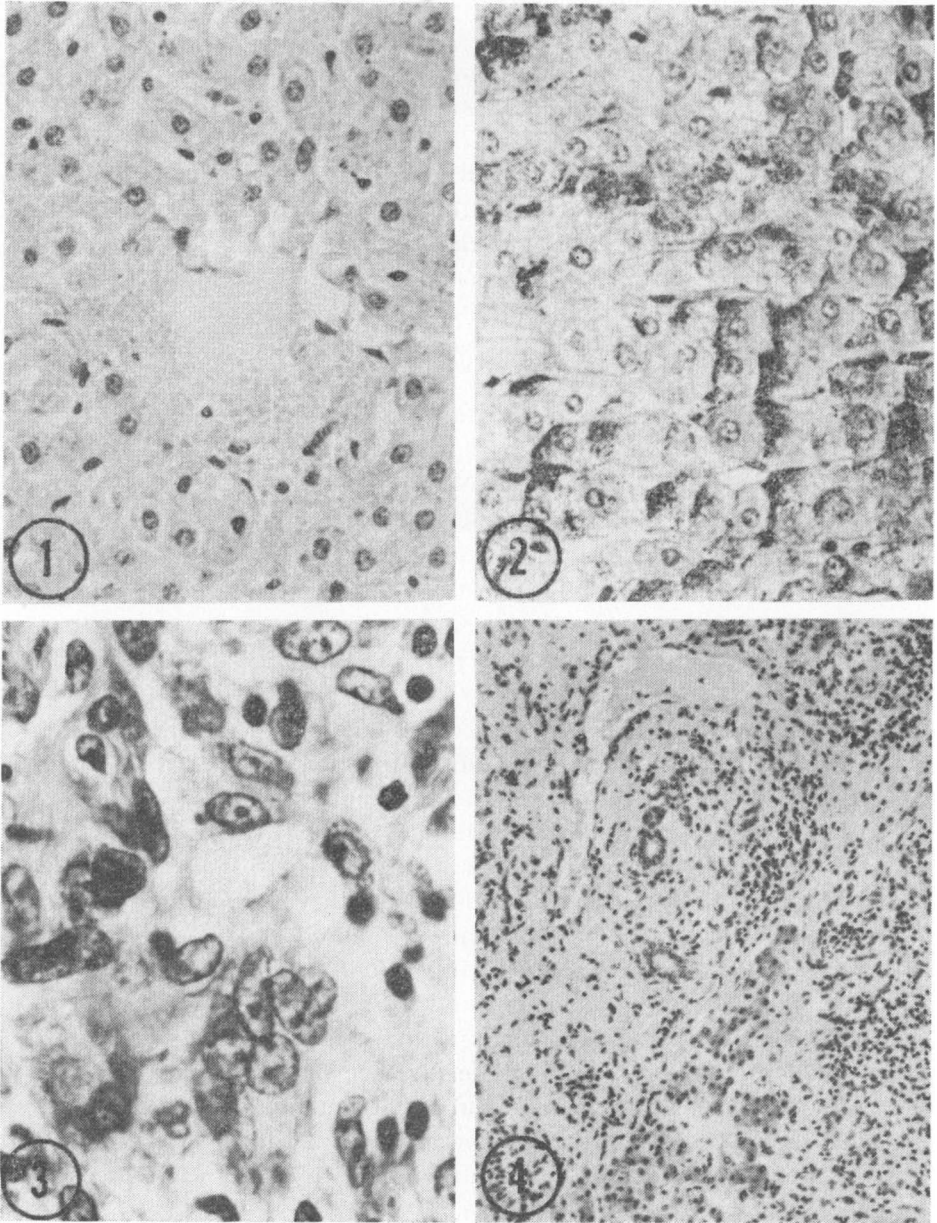
The liver material originates from slaughtered goats spontaneously infected with either *D. dendriticum* or *F. hepatica*. Tissue blocks from different sections of the liver and bile ducts were fixed in 10 % neutral formalin prior to routine paraffin embedding. Sections cut at 5 μ were stained with haematoxylin and eosin (HE).

Selected sections were stained with van Gieson's haematoxylin-picrofuchsin staining and according to Ladewig's modification of Masson's trichrom method for collagen, with Weigert's staining for fibrin, Gomori's staining for elastic fibres and silver impregnation for reticulin fibres, as described by *Romeis* (1948) and *Roulet* (1948). Iron was studied by Hueck's modification of Tirmann's and Schmelzer's Turnbull method and calcium with von Kossa's silver nitrate staining (*Roulet*). For the study of glycogen, periodic acid-Schiff and Best's carmine methods were used, with or without previous diastase digestion according to *McManus & Mowry* (1960). The diastase digestion was carried out with an 0.5 % aqueous solution of malt diastase (Diastase 2800 u./g, Merck) at room temperature for 20 min. Neutral fats were revealed by staining frozen section with oil red 0 (*Romeis*).

RESULTS

The liver

In dicrocoeliasis the liver parenchymal cells were degenerated in varying degrees, evidently depending on the intensity of the infection. The liver cells, normally presenting a fine-granular basophilia in the cytoplasm, were swollen, displaying a pale, often vacuolated cytoplasm (Fig. 1). The glycogen of the cells



- Figure 1. Dicrocoeliasis. Centrilobular area, showing degenerated liver parenchymal cells. HE \times 370.
- Figure 2. Fascioliasis. Glycogen of liver parenchymal cells is decreased and irregularly distributed. Best's carmine, haematoxylin counterstain \times 370.
- Figure 3. Fascioliasis. Section through a healing migratory track of the liver fluke, showing multinucleated giant cells and macrophages. HE \times 630.
- Figure 4. Fascioliasis. Section through scar produced by migrating flukes. HE \times 160.

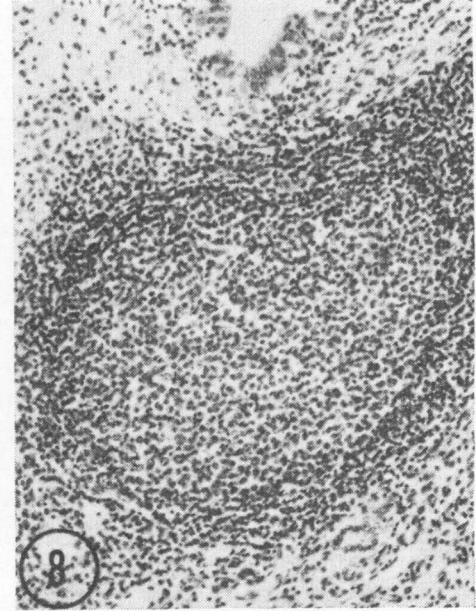
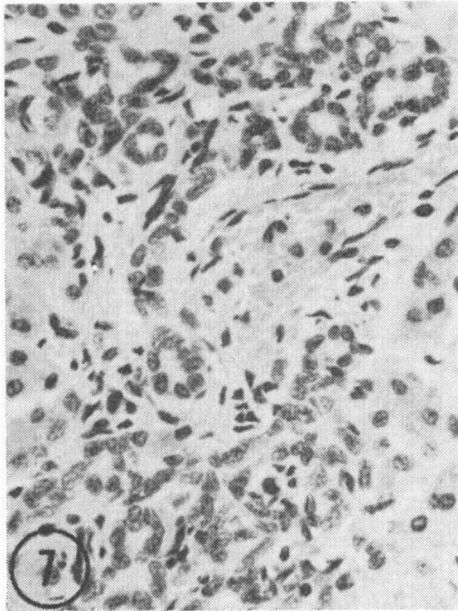
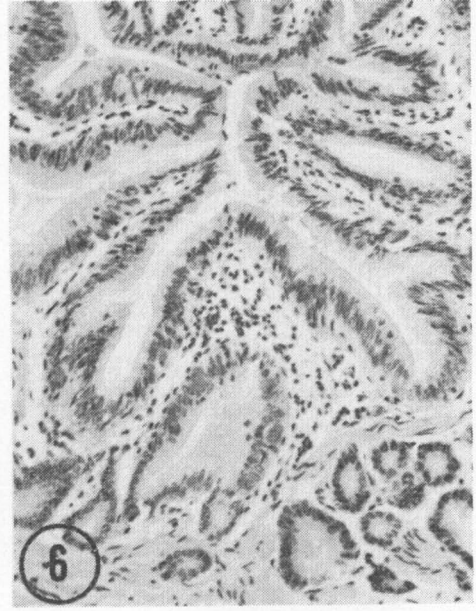
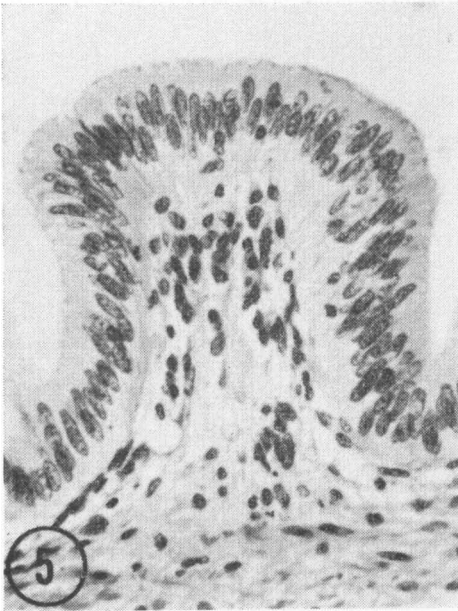
was considerably decreased, whereas neutral fats were present in increased amounts. Fat infiltrations were usually diffuse in distribution. On the other hand the depletion of glycogen from liver cells varied from zone to zone of the liver lobuli. Occasionally liver cells also presented a few lipofuscin or haemosiderin granules. In fascioliasis the appearance of the liver parenchymal cells was rather similar (Fig. 2).

Dicrocoeliasis was characterized by a moderate general inflammatory reaction. The inflammatory cells, including both round cells and polymorphonuclear granulocytes, were usually diffusely distributed in the sinusoids, while the interlobular zones and perivascular areas in sections near to thickened bile ducts also presented distinct foci of these cells. Only a few phagocytosing macrophages displayed brown haemosiderin accumulations in the cytoplasm. Furthermore, occasional granulomata formed by macrophages and multinucleated giant cells were present in some livers. In all infected livers the hepatic framework was pronouncedly increased but only regionally. The increase of mesenchymal tissues, both of collagen and reticulin fibres, was concentrated in the visceral sections of the livers, where the connective tissues spread from the thickened walls of bile ducts to the adjoining parenchymal tissues and the hepatic capsule. In such areas the portal zones were connected by fibrotic tissues, and pseudolobuli formations were usual. The increase of reticulin fibres was particularly prominent around central veins, producing thickening of their walls. The walls of the blood vessels in fibrotic interlobular areas were also thickened but no thrombotic processes were present.

The above description of the inflammatory response and fibrosis in dicrocoeliasis largely applies also to fascioliasis, but two main differences were observed. Firstly, the inflammatory reaction was pronounced in areas containing migratory tracks of *F. hepatica* (Fig. 3). Secondly, in fascioliasis the fibrotic tissues accompanying the alteration in the walls of bile ducts were distinctly more prominent than in dicrocoeliasis. The fibrosis of the liver in fascioliasis was accordingly more pronounced and irregular than in dicrocoeliasis (Fig. 4).

The bile ducts

The normal bile ducts of the interlobular areas were lined with cubical epithelial cells with weakly basophilic cytoplasm.



- Figure 5. Normal bile duct, showing regular surface epithelium with high-columnar epithelial cells. HE \times 630.
- Figure 6. Dicrocoeliasis. Proliferations of epithelial cells in moderate-sized intrahepatic bile duct. HE \times 370.
- Figure 7. Dicrocoeliasis. Interlobular tissue, showing irregularly proliferating small bile ductules. HE \times 370.
- Figure 8. Fascioliasis. Section through wall in a main bile duct damaged by flukes. This section is poor in glands, presenting simple surface epithelium and well-defined lymphatic nodule in fibrotic subepithelial tissues. HE \times 370.

In the larger intrahepatic bile ducts the epithelial cells became gradually higher, and those in the main bile ducts were high-columnar in shape (Fig. 5). These ducts also carried short villi covered by the surface epithelium, showing a few goblet cells. Two types of glands were present in their walls. The first type was the superficial gland, which was usually located in areas below the crypts of the surface epithelium and showed cells similar to those in the neck of the villi. The second type, the deep gland, had cells which were cubical, showing a pale vacuolated cytoplasm. The deep glands were present only in the deeper sections of the walls and increased in frequency in the direction of the bile flow.

Dicrocoeliasis produced a moderate proliferation of both the epithelial and mesenchymal tissues in the walls of the main bile ducts used by the migrating lancet flukes. In addition, the simple epithelium of moderately-sized intrahepatic bile ducts was transformed to a thick mucosa, owing to the development of villous processes, covered by high-columnar epithelial cells, and the fibrotic interlobular areas also presented irregularly proliferating small bile ductules (Figs. 6 and 7). The mucosa of the main bile ducts was moderately thickened, primarily owing to the proliferation of epithelial cells in the crypts and superficial glands, and goblet cells were frequent. The lamina propria was oedematic, intensely infiltrated by inflammatory cells and surrounded by a thick peripheral layer of fibrotic tissues. The lancet flukes were usually lying in close contact with the mucosa of the main bile ducts, compressing the villi and producing desquamation of epithelial cells in their tips. However, the erosions were only superficial and never damaged the underlying basal membrane. No staining reaction for calcium was seen in different sections of the walls. The epithelium of bile ducts of all sizes frequently showed globule leucocytes.

In fascioliasis the changes in the walls of the bile ducts were broadly similar to those produced by dicrocoeliasis, but more extensive. Thus the glandular proliferations formed a pronouncedly thickened mucosa, which in the main bile ducts was deeply eroded by the liver flukes. Some ulcers penetrated as far as to the extensively thickened peripheral fibrous layer. Increased fibrosis was observed in the tunica propria, too, particularly in areas damaged by the flukes (Fig. 8).

DISCUSSION

In the present study the pathological phenomena produced by *dicrocoeliasis* were compared with those occurring in *fascioliasis*. Though there are considerable differences in the morphology and life-cycle of the parasites responsible for these diseases, the pathological changes produced by them in the liver and bile duct of the goat have many features in common. However, differences are to be observed in the extent and severity of the lesions, and the changes occurring in *fascioliasis* are much more pronounced than those in *dicrocoeliasis*. This agrees well with the observations previously reported by *Soulsby* (1965).

The differences observed in the degree of the lesions produced by *Dicrocoelium* and *Fasciola* partly originate from the different migratory routes of these parasites. The lancet fluke enters the common bile duct by its intestinal opening, migrates as far as to the small bile ducts but never penetrates the bile-duct walls (*Krull* 1958). On the other hand, the liver fluke penetrates the hepatic capsule, migrating in the liver parenchyma for several weeks until it enters the bile ducts by direct penetration of their walls and reaches maturity in the main bile ducts (*Rahko* 1971). *Fasciola* thus destroys liver tissues, producing migrational tracks which are healed by fibrous tissue. Since it migrates at random, the scars resulting from the migratory tracks distort the architecture of the goat liver over large areas. Similar scars are not seen in *dicrocoeliasis*. On the other hand, in *dicrocoeliasis* the fibrosis observed in the bile-duct walls and the interlobular zones is almost comparable to that produced by *fascioliasis*.

The dissimilarity in the structure of the tegument represents one of the most striking morphological differences between *Dicrocoelium* and *Fasciola*. The tegument of *Fasciola* carries sharp cuticular spines, which produce extensive desquamation of bile-duct epithelial cells in cattle (*Rahko* (1969). Deep erosions are seen in the bile-duct walls of the goat, too, but only in *fascioliasis*, erosion being inconsiderable in *dicrocoeliasis*. Since the lancet fluke is small in size and possesses a smooth tegument, it is believed to produce less mechanical irritation than the liver fluke (*Soulsby, Sinclair* 1967). It seems probable that the erosions observed in *dicrocoeliasis* of the goat were produced by the suckers of the lancet flukes.

The liver parenchymal cells of the goat degenerate in both

dicrocoeliasis and fascioliasis. The cells become depleted of glycogen but show increased fat infiltration. This confirms the observations reported by *Dhar & Singh* (1963) on hill-bulls infected with *Dicrocoelium*. However, it seems likely that the degree of infection is decisive with respect to the degeneration of the liver (*Rahko* 1971). According to previous studies, this applies also to the clinical pathology of these parasitic diseases (*Soulsby, Sinclair*).

ACKNOWLEDGEMENT

The author wishes to express his gratitude and thanks to Dr. Ole Sparboe, Statens Veterinære Laboratorium for Nord-Norge, Harstad, for providing the main part of the collected material.

REFERENCES

- Bengtsson, E., L. Hässler, P. Holtenius, F. Nordbring & G. Thoren:* Infestation with *Dicrocoelium dendriticum* — the small liver fluke — in animals and human individuals in Sweden. *Acta path. microbiol. scand.* 1968, 74, 85—92.
- Dhar, D. N. & K. S. Singh:* Histochemical studies on liver in dicrocoeliasis. *Indian J. vet. Sci.* 1963, 33, 142—151.
- Krull, W. H.:* The migratory route of the metacercaria of *Dicrocoelium dendriticum* (*Rudolphi*, 1819, *Looss*, 1899) in the definitive host: *Dicrocoeliidae*. *Cornell Vet.* 1958, 48, 17—24.
- McManus, J. F. A. & R. W. Mowry:* Staining Methods: Histologic and Histochemical. Paul B. Hoeber, Inc., New York 1960.
- Rahko, T.:* The pathology of natural *Fasciola hepatica* infection in cattle. *Path. Vet.* 1969, 6, 244—256.
- Rahko, T.:* Studies on the pathology of bovine and murine liver infected with *Fasciola hepatica* with reference to the mast cell and globule leucocyte. Thesis. *Ann. Acad. Sci. fenn. A* 5 1971, 148, 1—62.
- Romeis, B.:* Mikroskopische Technik. (Microscopical technique). R. Oldenbourg, München 1948.
- Roulet, F.:* Methoden der Pathologischen Histologie. (Methods of histopathology). Springer, Wien 1948.
- Sinclair, K. B.:* Pathogenesis of *Fasciola* and other liver-flukes. *Helminth. Abstr.* 1967, 36, 115—134.
- Soulsby, E. J. L.:* Textbook of Veterinary Clinical Parasitology. Blackwell Scientific Publications, Ltd., Oxford 1965.

SAMMANFATTNING

Undersökningar med avseende på dicrocoeliasis- och fascioliasis-infektionens patologi hos get. I. Leverns och gallgångarnas histopatologi.

Jämförande undersökningar har utförts med avseende på leverns och gallgångarnas histopatologi vid dicrocoeliasis och fascioliasis

hos get. Fynden visade en del likheter hos de patologiska förändringarna orsakade av *D. dendriticum* och *F. hepatica*. Fascioliasis visade i motsats till dicrocoeliasis karakteristiska migrationsgångar i leverparenkymet orsakade av omogna leverflundror. Skadorna orsakade av fascioliasis var dessutom mer prononcerade än vid dicrocoeliasis.

Hos vardera parasitära sjukdom visade gallgångsväggarna en körtelaktig hyperplasi, ökad frekvens av bägarceller och globule leukocyter och prononcerad fibros i perifera skikt. Av *Dicrocoelium* orsakade deskvamationer var superficiella medan *Fasciola* visade djupgående erosioner i väggarna hos de stora gallgångarna. Förkalkningar observerades dock inte. Ökad fibros påvisades i de interlobulära områdena men en prononcerad desorganisation observerades endast vid fascioliasis orsakad av ärrbildningar utgående från helnade migrationsgångar. Levercellerna var ofta degenererade och visade minskad glykogenhalt och infiltration med neutralt fett i tilltagande mängder.

(Received November 19, 1971).

Reprints may be requested from: Timo Rahko, Department of Pathology, College of Veterinary Medicine, Hämeentie 57, Helsinki 55, Finland.